

CC: Chest pain

HPI: Went to meet a friend for breakfast at Starbucks. Had a triple shot latte, and about 20 minutes later started feeling his heart race. This was accompanied by some central chest pressure and mild SOB.

PMH: HTN, PAF

Meds: Toprol XL 100mg QD (but forgot to take today)
Coumadin 5mg QD

ALL: NKDA

FHx: None

SHx: Neg x 3

ROS: As per HPI. No recent illnesses. He is now starting to feel lightheaded as well.

Physical Exam (Sim findings in bold):

VS: Per **monitor 37.5 135 AF 100/60 20 96%**

Gen: Mild distress.

HEENT: PERRL 3mm. No pallor. TM, MM, pharynx nl.

Neck: No bruits. No thyromegaly

CV: **Irregularly irregular tachycardia. Pulses present.**

Lungs: **Rales bilaterally**

Abd: Normoactive BS. Soft

Skin: **Dry no rashes or ecchymoses**

Extremities: **No edema.**

Rectal: Normal tone, nontender, hemocult neg.

Neuro: **Eyes open.** GCS 15. Normal.

CBC

WBC	12.4
Hb	15.0
Hct	44.0
PLT	350

N	62
B	0
L	35
M	2
E	

CMP

Na	135
K	4.8
Cl	108
HCO ₃	24
BUN	30
Cr	1.0
Glc	112

Ca	8.4
T Protein	7.4
Alb	3.9
AST	42
ALT	35
ALK	120

Urine Toxicology

Alcohol	neg
Cocaine	neg
Barbituates	neg
Opiates	neg
Benzodiazepines	neg
PCP	neg
Amphetamines	neg

Urinalysis

WBC	1-2
RBC	3-5
Protein	neg
Glucose	neg
Ketones	neg
Squamous Cells	small
Nitrite	neg
Leuk Est	neg

Cardiac Enzymes

CK-MB	1.3
CK TOTAL	184
Troponin	< 0.03

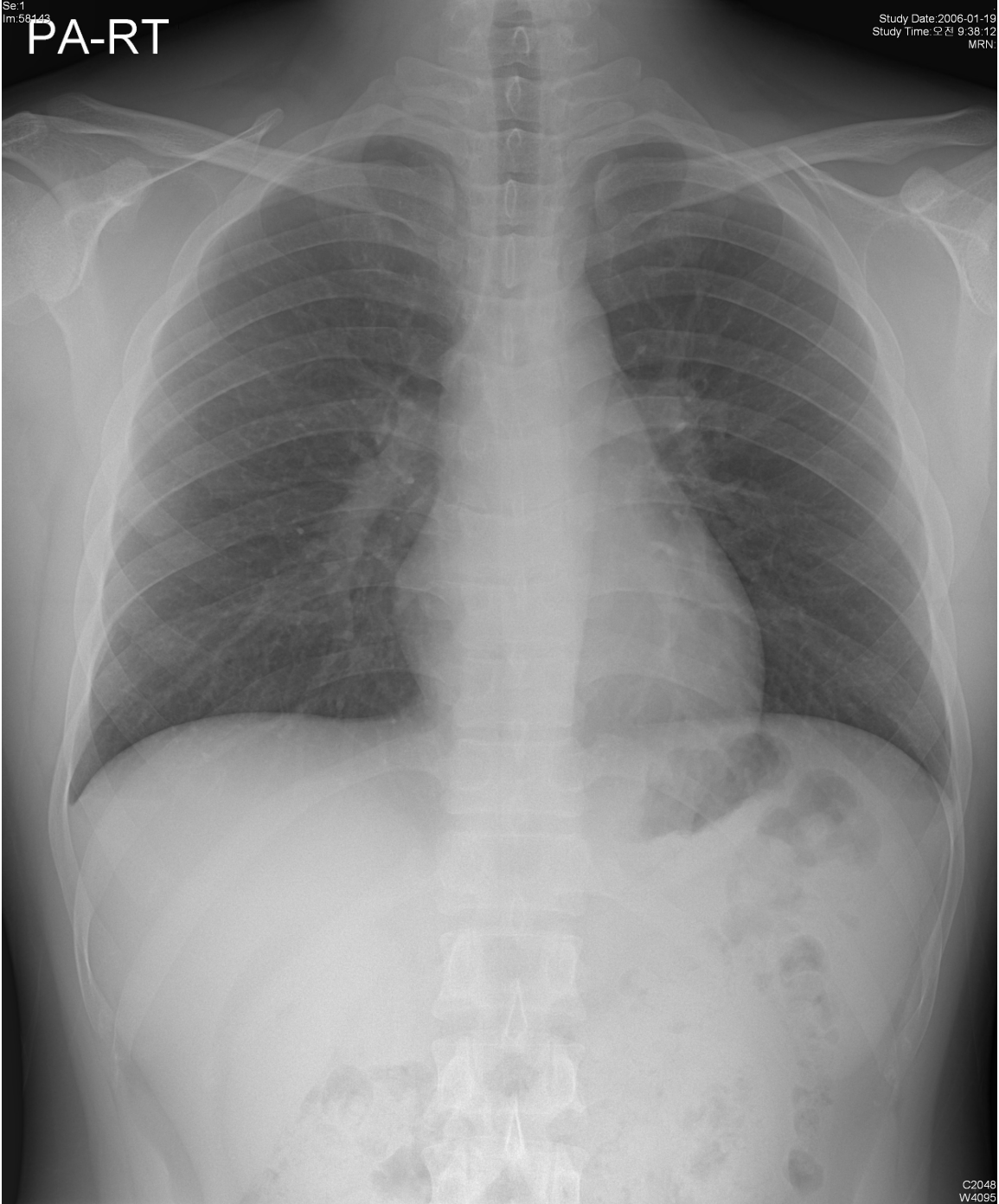
Coagulation Profile

INR	2.5
-----	-----

Se:1
Im:58/63

PA-RT

Study Date: 2006-01-19
Study Time: 오전 9:38:12
MRN:

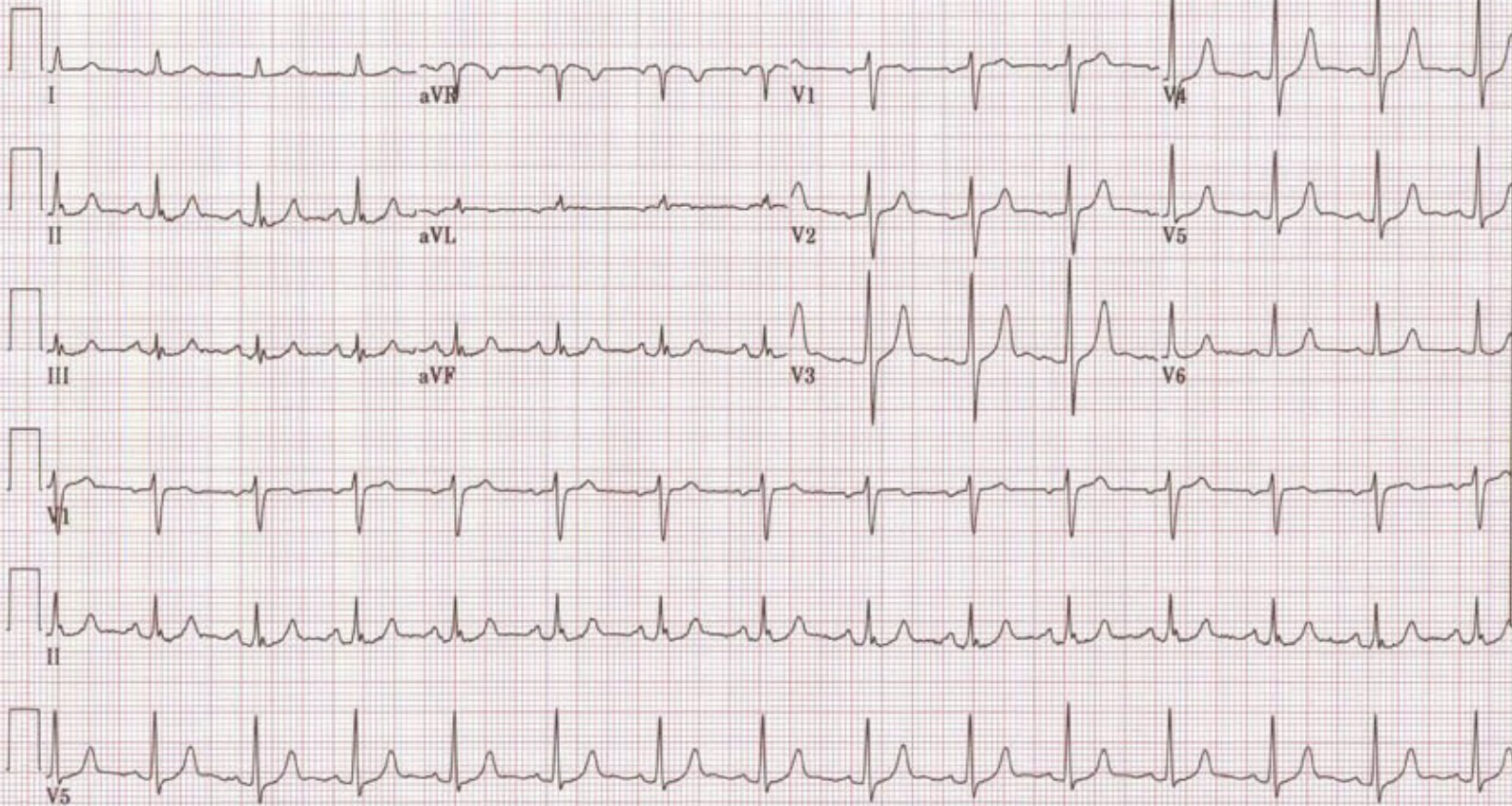


C2048
W4095

TEST 100.01

Referred by: Dept. Emergency-Room

Confirmed By:



25mm/s 10mm/mV 100Hz 005C 12SL 250 CID: 59

EID:9001 EDT: 13:01 24-APR-2001 ORDER: 22087204

Page 1 of 1