

"INDIGESTION"

Pt ID: 58 yo male

CC: Indigestion

HPI: Approximately 1 month of epigastric pain occurring after eating (about 30minutes later). Lasts up to an hour, is accompanied by nausea. Pt is sedentary (desk job), lives in a ranch (1 level) so has never noted this pain with exertion. Today he had lunch out with associates (double cheeseburger, fries and a shake). The pain started in the car coming back from the restaurant, and worsened as he was walking back to his office. He tried Maalox and Tums from his desk without relief, and against his wishes, his co-workers brought him in. It's been going on for about 45 minutes.

ROS: Negative except as above

PMHx: None (hasn't seen a doc in over 20 years)

Meds: None

Allergies: NKDA

FHx: None known (although if asked about sudden death, Dad died suddenly at 49, cause unknown)

SHx: EtOH on weekends, 2ppd tobacco x 25years, no illicit

Physical Exam (Sim findings in bold):

WDWN 58 male appears uncomfortable

VS: Per **monitor 37.5 160/90 110 20 98%**

Gen: Mild distress.

HEENT: **Reactive 4mm bilaterally.** MMM.CV: **Normal rate No M/R. (+) S4 Symmetric pulses.** Laterally displaced PMI. No JVD.Lungs: **CTAB**

Abd: Normal BS. Soft, NTND.

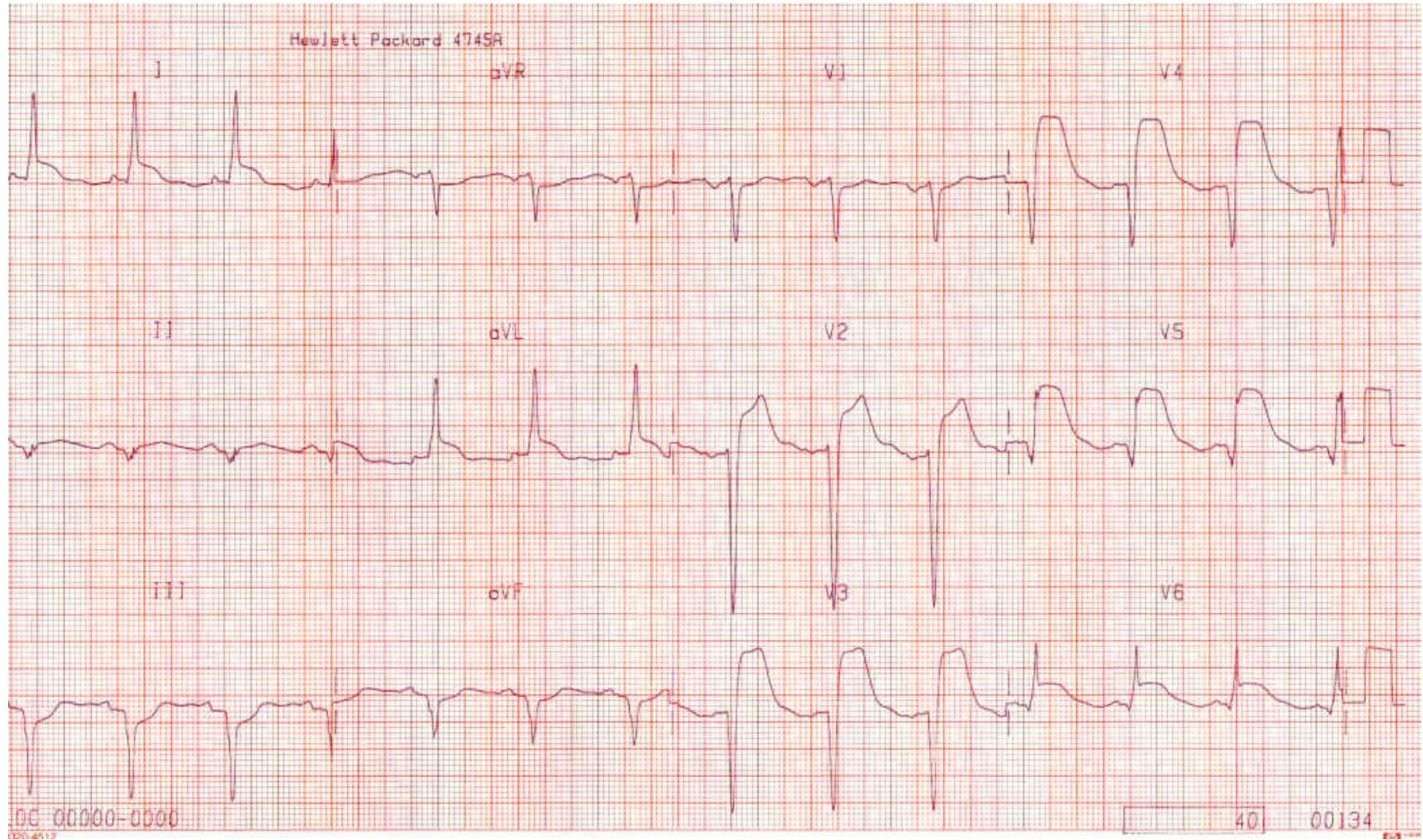
Skin: Warm, dry. No lesions.

Extremities: No edema.

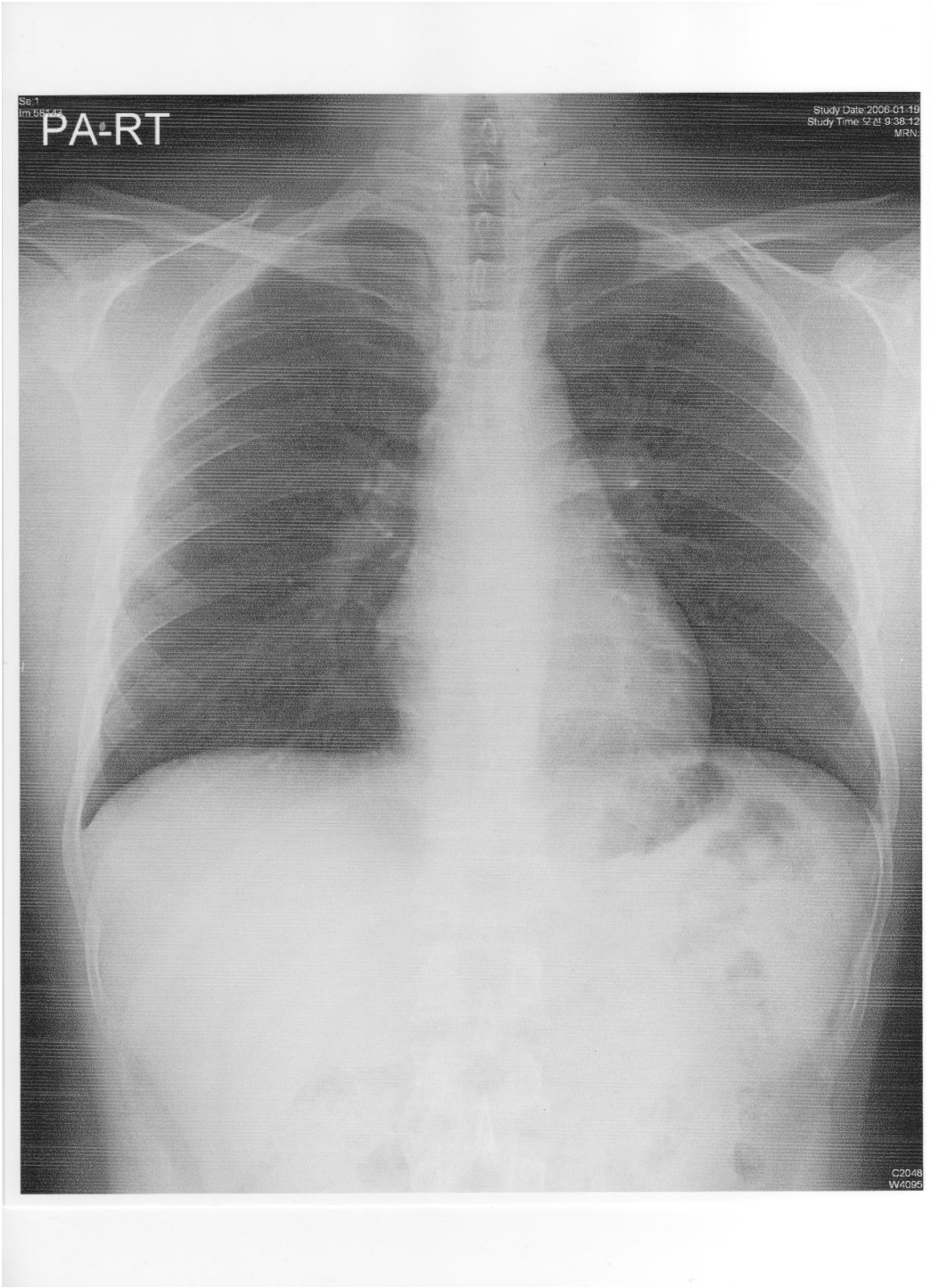
Rectal: Normal tone, nontender, hemoccult neg. Brown stool.

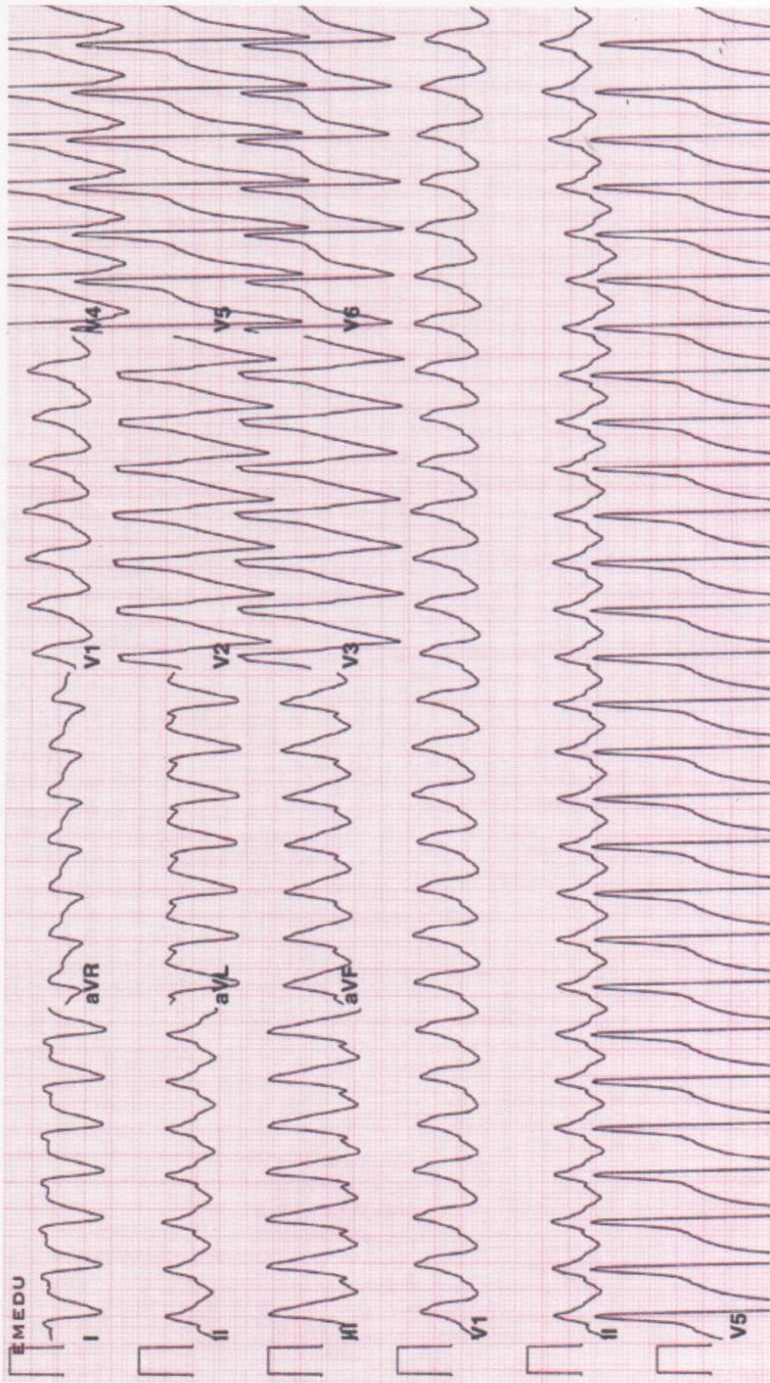
Neuro: **Eyes open spontaneously.** CN intact. NI motor and sensory. No dysmetria or past-pointing. Normal reflexes

CS1



CS1





CS1

CBC

WBC	16.4
Hb	15.0
Hct	44.0
PLT	350

N	75
B	0
L	3
M	2
E	

CMP

Na	135
K	4.8
Cl	108
HCO3	24
BUN	30
Cr	1.2
Glc	112

Ca	8.4
T Protein	7.4
Alb	3.9
AST	42
ALT	35
ALK	120

CS1

Urine Toxicology

Alcohol	neg
Cocaine	neg
Barbituates	neg
Opiates	neg
Benzodiazepines	neg
PCP	neg
Amphetamines	neg

CS1

CK-MB	10.3
CK TOTAL	184
Troponin	1.6