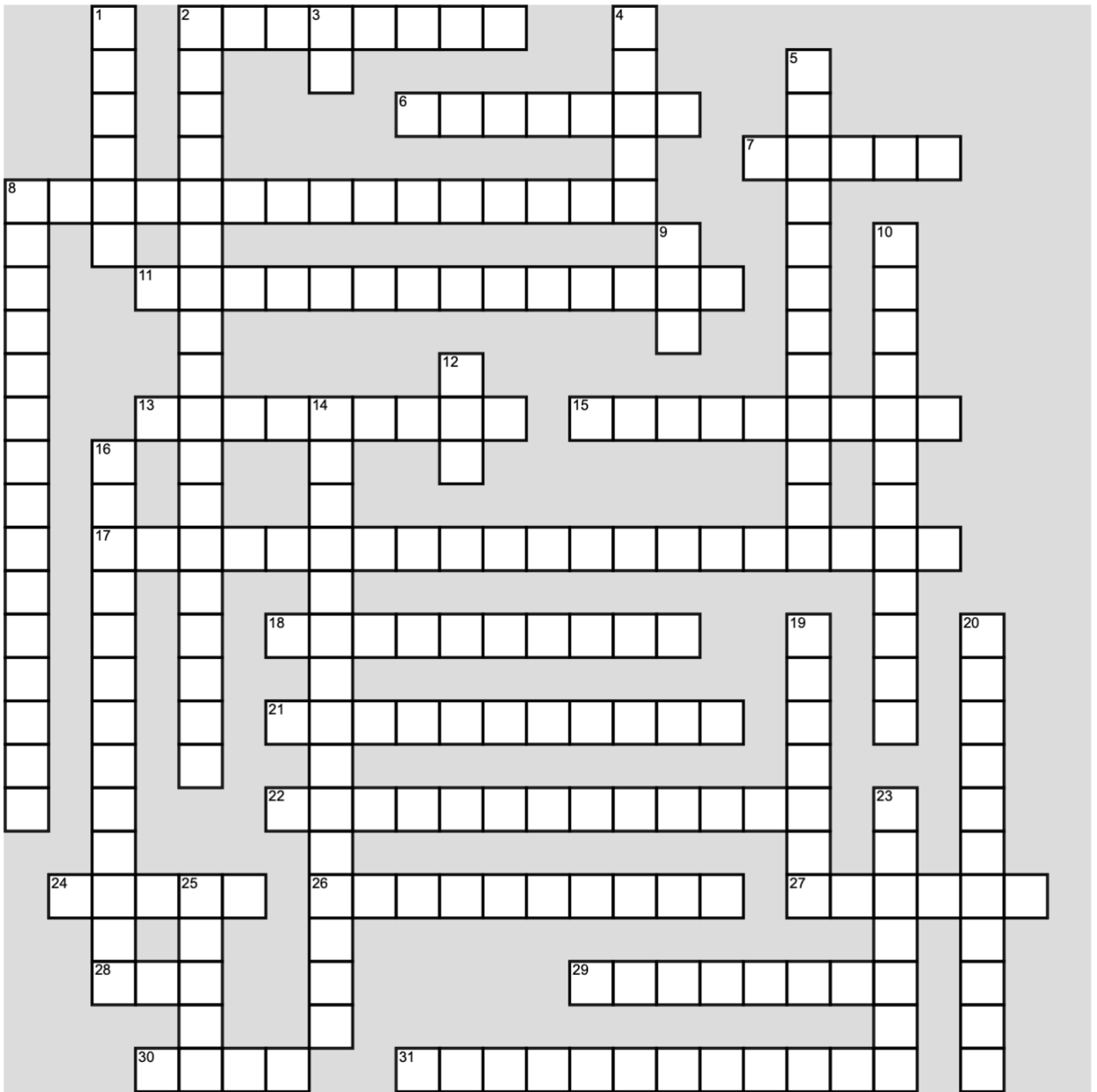


Crossy Crossword

Credits: Robert Stenberg, UNC/VCU/CCAG EM Residencies, FOAMed

- Judge/Proctor: Someone!
- Equipment
 - Judge
 - Sheets: (Crossword Puzzle x #Participants) + 1 Answer key
 - Pens paper
 - Station score sheet
- Game: 15 minutes
 - Guess Word
 - Correct or incorrect
 - Incorrect
 - Keep guessing
 - Correct
 - Write it in
- Clue
 - Up to 3 clues
 - -1 point per clue given
 - Make up clue at your discretion; please don't just tell them the word
- Points
 - 5 pts/word
 - 20 pts extra if get whole board; maybe even more no group has done yet



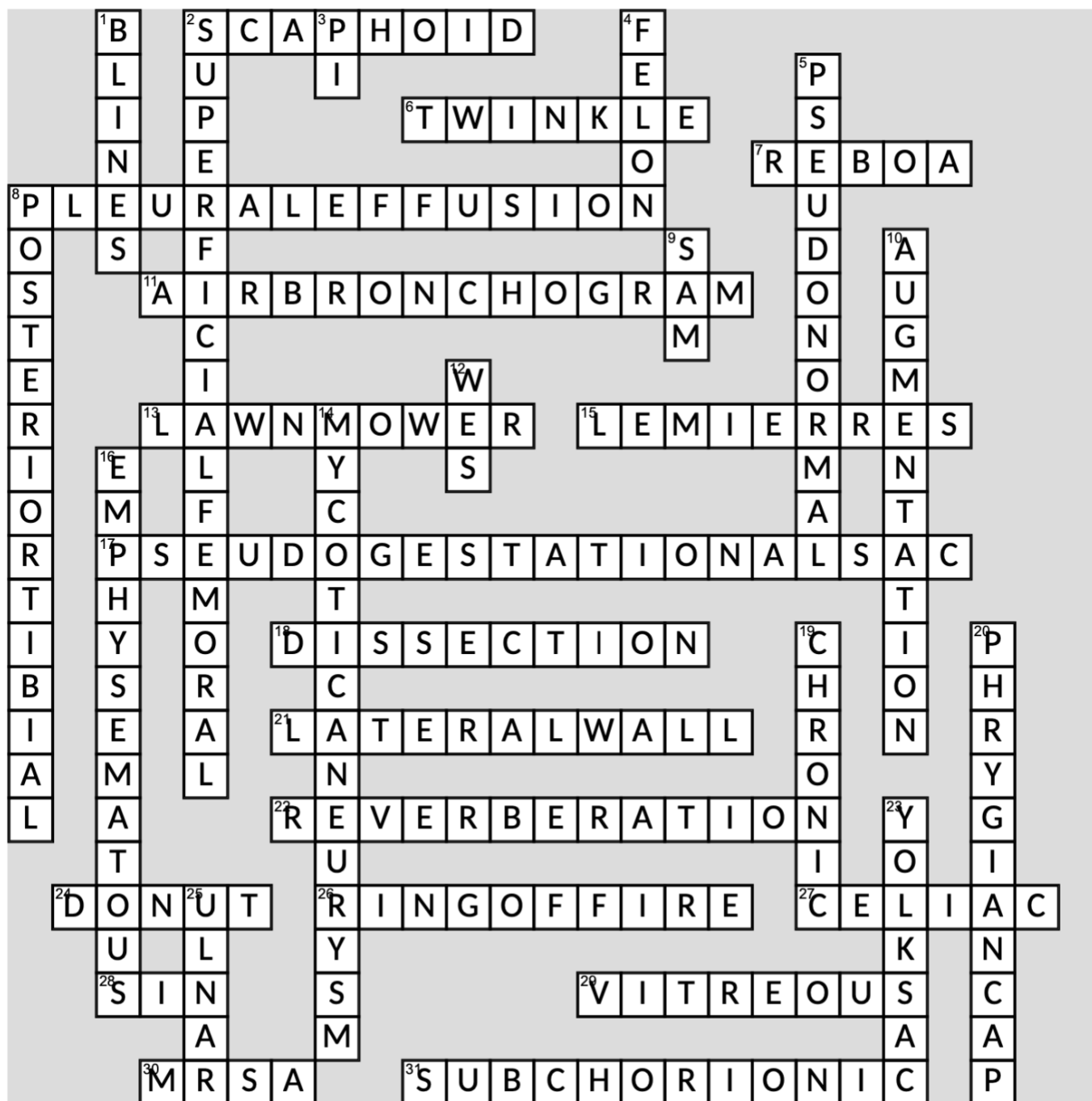
Across

- 2 There's a crack in the boat
- 6 Stone at UVJ
- 7 You see a nitinol wire extending into Zone 1
- 8 Fluid collection posterior to aorta
- 11 Dynamic lung finding indicative of pneumonia
- 13 Landscape for the appy
- 15 Septic thrombophlebitis
- 17 FakeOut Pregger
- 18 Intima separated from media
- 21 Gallbladder's shadowing trick to make you think there is a stone
- 22 Lung A lines demonstrate which artifact
- 24 Homer Simpson Loves intussusception
- 26 Johnny Cash Appy
- 27 Dissecting right through the seagull
- 28 When it doesn't change with positions, and you should cut it out
- 29 Dynamic membrane only seen at high gain
- 30 Abscess is <1cm, has ill-defined edge, irregularly shaped
- 31 Hypochoic fluid between placenta and uterus

Down

- 1 What you should not see with a pneumo
- 2 R/O DVT here after bifurcation of CFV
- 3 Pyloric Stenosis
- 4 Hypochoic fluid collection near distal phalanx
- 5 E/A grade II
- 8 Block for the plantar foot foreign body
- 9 Sonographic evidence of obstruction in HCM
- 10 Squish the leg, r/o DVT
- 12 When you misinterpreted the gallbladder for loop of bowel and may need it out
- 14 IVDU, fever leg pain bruit
- 16 Dirty shadowing in wall of gallbladder
- 19 Deep vein is echogenic, has web-like filling defects, and thick wall
- 20 Gallbladder normal variant
- 23 Claim it an IUP
- 25 Block the interossei

ANSWER KEY



ANSWER KEY

Across

- 2 There's a crack in the boat
- 6 Stone at UVJ
- 7 You see a nitinol wire extending into Zone 1
- 8 Fluid collection posterior to aorta
- 11 Dynamic lung finding indicative of pneumonia
- 13 Landscape for the appy
- 15 Septic thrombophlebitis
- 17 FakeOut Pregger
- 18 Intima separated from media
- 21 Gallbladder's shadowing trick to make you think there is a stone
- 22 Lung A lines demonstrate which artifact
- 24 Homer Simpson Loves intussusception
- 26 Johnny Cash Appy
- 27 Dissecting right through the seagull
- 28 When it doesn't change with positions, and you should cut it out
- 29 Dynamic membrane only seen at high gain
- 30 Abscess is <1cm, has ill-defined edge, irregularly shaped
- 31 Hypochoic fluid between placenta and uterus

Down

- 1 What you should not see with a pneumo
- 2 R/O DVT here after bifurcation of CFV
- 3 Pyloric Stenosis
- 4 Hypochoic fluid collection near distal phalanx
- 5 E/A grade II
- 8 Block for the plantar foot foreign body
- 9 Sonographic evidence of obstruction in HCM
- 10 Squish the leg, r/o DVT
- 12 When you misinterpreted the gallbladder for loop of bowel and may need it out
- 14 IVDU, fever leg pain bruit
- 16 Dirty shadowing in wall of gallbladder
- 19 Deep vein is echogenic, has web-like filling defects, and thick wall
- 20 Gallbladder normal variant
- 23 Claim it an IUP
- 25 Block the interossei

WORD LIST:

AIRBRONCHOGRAM	LATERALWALL	PSEUDOGESTATIONALSAC	SUPERFICIALFEMORAL
AUGMENTATION	LAWNMOWER	PSEUDONORMAL	TWINKLE
BLINES	LEMIERRES	REBOA	ULNAR
CELIAC	MRSA	REVERBERATION	VITREOUS
CHRONIC	MYCOTICANEURYSM	RINGOFFIRE	WES
DISSECTION	PHRYGIANCAP	SAM	YOLKSAC
DONUT	PI	SCAPHOID	
EMPHYSEMATOUS	PLEURALEFFUSION	SIN	
FELON	POSTERIORTIBIAL	SUBCHORIONIC	